

## Double mesiodens concomitant with missing lateral incisors: a case report

Case Report

### Abstract

**Introduction:** One of the extremely rare conditions is the simultaneous occurrence of both hypodontia and hyperdontia in the same individual, known as hypo-hyperdontia or the concomitant hypodontia and hyperdontia (CHH). The prevalence of hypo-hyperdontia is estimated between 0.002% and 3.1%. The etiology of this unusual condition still remains undetermined.

**Case presentation:** In the present case we report a patient with double mesiodens, coincide with missing primary and permanent lateral incisors.

**Conclusion:** Both mesiodens were extracted to prevent its adverse effects on the permanent dentition.

**Key words:** Hypodontia, hyperdontia, hypo-hyperdontia, mesiodens

Solhjoo N<sup>1\*</sup>

Razmjouei F<sup>2</sup>

1. Postgraduate Student, Department of Pediatric Dentistry, School of Dentistry, Shiraz University of Medical Sciences, Shiraz, Iran.

2. Oral and Dental Disease Research Center, School of Dentistry, Shiraz University of Medical Sciences, Shiraz, Iran

Corresponding Author:

[solhjoo\\_neda@yahoo.com](mailto:solhjoo_neda@yahoo.com)

## مورد نادر از مزبودنس دوتایی همزمان با غیبت دوطرفه انسیزورهای طرفی ماگزایلا: گزارش

مورد

چکیده

## گزارش مورد

ندا صلح جو<sup>۱</sup>  
فرانک رزمجویی<sup>۲</sup>

۱. رزیدنت اطفال، گروه دندانپزشکی کودکان، دانشکده دندانپزشکی، دانشگاه علوم پزشکی شیراز، شیراز، ایران.

۲. استادیار مرکز تحقیقات بیماری‌های دهان و دندان، دانشکده دندانپزشکی، دانشگاه علوم پزشکی شیراز، شیراز، ایران.

نویسنده مسئول: دکتر ندا صلح جو

[solhjoo\\_neda@yahoo.com](mailto:solhjoo_neda@yahoo.com)

تاریخ دریافت: ۹۷/۹/۴

تاریخ پذیرش: ۹۸/۳/۱۵

**مقدمه:** یکی از وضعیت‌های تکاملی بسیار نادر وقوع همزمان دندان اضافه (hyperdontia) و غیبت دندانی (hypodontia) در یک فرد می‌باشد که hypo-hyperdontia یا concomitant hypodontia and hyperdontia (CHH) نامیده می‌شود. شیوع hypo-hyperdontia به طور تقریبی  $1/3 - 0.02/0\%$  تخمین زده شده است. علت ایجاد این وضعیت هنوز ناشناخته می‌باشد.

**گزارش مورد:** ما در اینجا به گزارش موردی با وقوع همزمان مزبودنس دوتایی و غیبت دوطرفه انسیزورهای طرفی شیری و دائمی ماگزایلا پرداخته ایم.

**نتیجه گیری:** در این بیمار هر دو مزبودنس به منظور پیشگیری از اثرات منفی بر دندان‌های دائمی خارج شدند.

**کلمات کلیدی:** دندان اضافه، غیبت دندانی، مزبودنس، هایپو-هایپرندنتیا

**Introduction:** The most frequent developmental dental anomaly in human being is the congenital absence of one or more teeth, called hypodontia. Without taking the third molars into account, the prevalence of hypodontia has been reported to be 1.6% - 9.6% in the general population.(1) The most frequently missing tooth is the mandibular second premolar, followed by the maxillary lateral incisor and the maxillary second premolar.(2) Another

frequent disturbance of odontogenesis is the supernumerary tooth, defined as an excess number of teeth or hyperdontia, with mesiodens being the most frequent.(3) A mesiodens with the overall prevalence of 0.15% - 1.9%, is a supernumerary tooth presented in the maxillary midline region.(4) The mesiodens may appear with a conical crown, usually smaller than the proximate normal teeth as a rudimentary morphology or it may also be found in a similar shape of

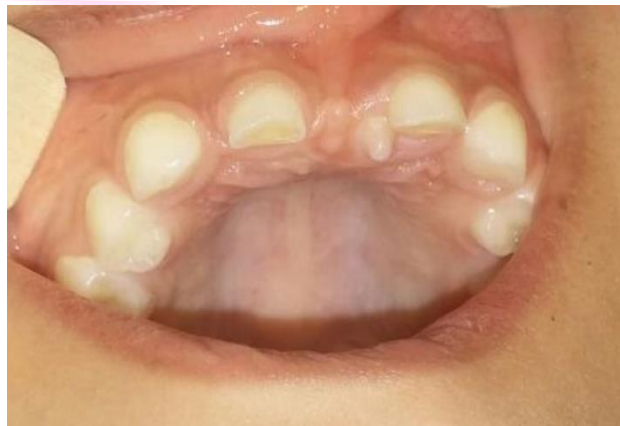the natural tooth. Spontaneous eruption of the mesiodens into the oral cavity occurs in only about 25% of all cases. Therefore, they are commonly detected during usual radiographic examination. (3) Mesiodens may have an impact on the eruption path and the location of the permanent incisors and subsequently alters both occlusion and appearance (4). One of the extremely rare conditions is hypo-hyperdontia, defined as the simultaneous occurrence of both hypodontia and hyperdontia in the same individual. (5) Based on a comprehensive literature review, the prevalence of hypo-hyperdontia is estimated between 0.002% and 3.1%.(1) While the supernumerary tooth is more common amongst males and the missing tooth amongst females, no obvious difference is shown in the prevalence of concomitant hypodontia and hyperdontia (CHH) between the two genders. (6) There are few case reports presenting the coincidence of two mesiodens with the missing of the second premolars.(7, 8) But to the best of our knowledge, no case has been reported with concomitant occurrence of twin mesiodens and bilaterally missing of lateral incisors.(1, 9) Through the present article we report a case of double mesiodens, coincide with missing primary and permanent lateral incisors.

**Case report :** An 8-year-old healthy male had been referred to the pediatric department of Shiraz Dental School, with the chief complaint of an extra tooth in his front region of the upper jaw since two years. There was no family history of hereditary tendency to the supernumerary or missing teeth. The history of trauma or extraction was also negative. The intraoral clinical examination disclosed mixed dentition with about 7 mm diastema between the upper primary central incisors along with a conical supernumerary tooth erupted palatally to the left primary central incisor, and the absence of both primary lateral incisors (Figure 1). Periapical radiographic examination exhibited another mesiodens which was impacted next to the right permanent central incisor, while both permanent central incisors were found with rotation in their position (Figure 2). Both of the mesiodens were conically in shape, vertically oriented and smaller in dimension as compared to the adjacent normal teeth. The extraction of the erupted mesiodens was done in the first visit due to parents' anxiety and insistency. Prior to any intervention, the informed consent was obtained from the patient's parents. A cone beam computerized tomography was taken, in order to assess the location and relationships of the impacted mesiodens to

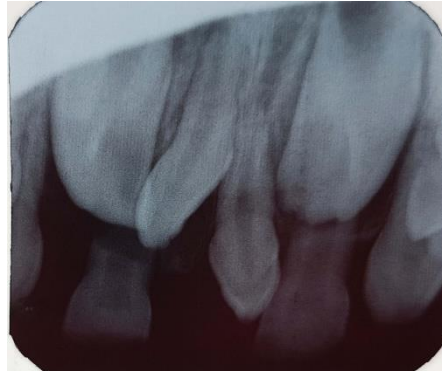the adjacent teeth and structures. In the CBCT report, the missing of both lateral permanent incisors was confirmed and the impacted mesiodens was shown to be in a very close position adjacent to the right permanent central incisor (Figure 3). Seven days after the first visit, a mucoperiosteal flap was raised in order to surgically extract the unerupted supernumerary tooth: First intracrevicular incision was made from the right deciduous canine to the left deciduous canine on the palatal side, and then a mucoperiosteal flap was elevated. Adequate bone removal on palatal cortical bone was done. Impacted mesiodens was removed carefully and the extraction socket was inspected for any pathological tissue. The flap was

repositioned and closed with 3-0 silk suture (Figure 4 and 5). After 1 week, when the patient returned for suture removal, an uneventful healing was achieved. The patient was recalled after 3 months to assess the central incisors for eruptive movements. The radiographic examination showed some corrections in the position of incisors but they were still not erupted due to the insufficient root development (Figure 6). Both central incisors erupted after 9 months but in a relatively rotate position (Figure 7). In order to manage the alignment of central incisors while considering the missing lateral incisors, consulting with orthodontics was considered. The result of consultation was to wait until the eruption age of permanent canines.

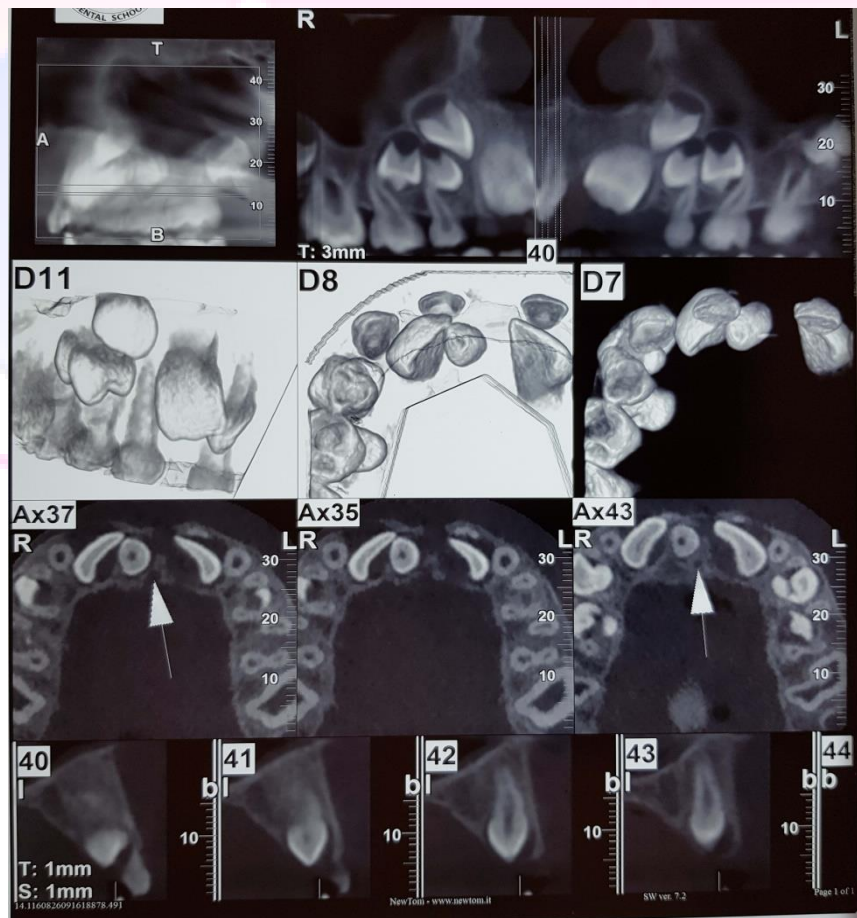
**Figure 1:** Intra-oral view of the maxillary arch. Note the diastema and the palatally erupted mesiodens.



**Figure 2:** Radiographic examination exhibited the impacted mesiodens, and rotated permanent central incisors.

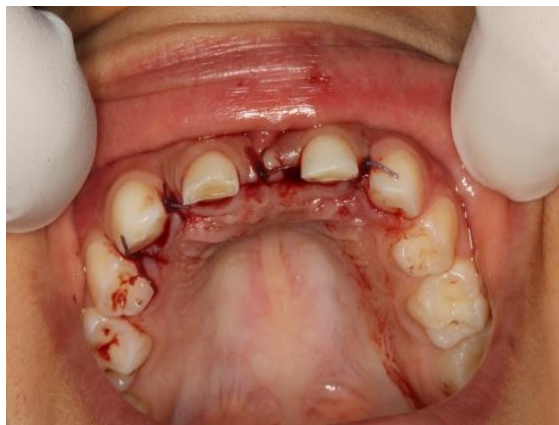

**Figure 3:** The CBCT showing the missed lateral permanent incisors and close position of the impacted mesiodens to the right permanent central incisor.

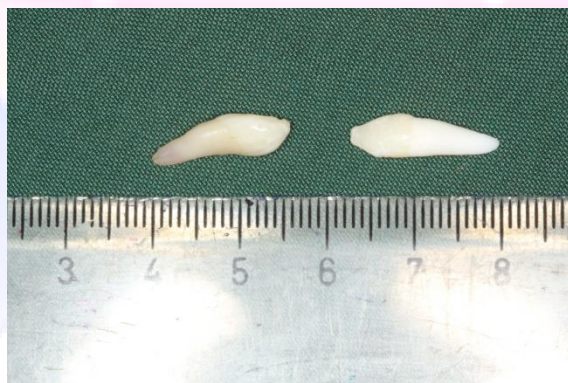



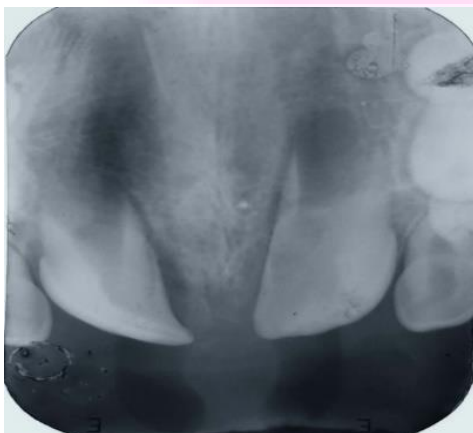**Figure 4:** Sutures in place after surgical extraction of the impacted mesiodens.



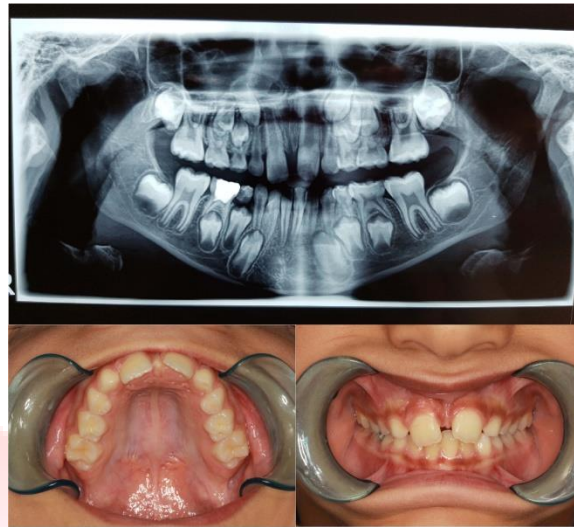
**Figure 5:** Both conical mesiodentes after extraction



**Figure 6:** Three months follow up: mild corrections in the position of incisors.



**Figure 7:** One year follow up: panoramic and photograph of dentition.



**Discussion :** In 1967 Camilleri defined the term “concomitant hypodontia and hyperdontia (CHH)”.(10) Subsequently, the term “hypo-hyperdontia,” was suggested by Gibson in 1979, which has been frequently used for describing this condition since then.(11) Although, the possible classification of premaxillary, maxillary, mandibular, and bimaxillary subdivisions of hypo-hyperdontia was presented by Gibson, no definitive classification has been propounded for this rare condition.(11) As in the present case, combination of missing maxillary lateral incisors and the presence of twin mesiodens would be defined as “premaxillary hypo-hyperdontia”, according to Gibson’s clasification. Transposition (the positional interchange of two adjacent teeth)

comes into mind when hypodontia and hyperdontia occur in the same jaw and quadrant. (12) However, neither CHH in different quadrants nor many cases of CHH in the same quadrant with atypical morphologies can be explained by this theory (13). Several ideas have been announced on the selectivity of tooth agenesis, but the theory of a polygenic multifactorial model of etiology still presents a good elucidation for hypodontia. (14) In a similar way, many theories have been proposed to explain the etiology of supernumerary teeth including atavism, dichotomy, hyperactivity of the dental lamina, and the concept of multifactorial inheritance. Nevertheless, the etiology of hypo-hyperdontia remains undetermined. It

has been proposed that the incidence of these anomalies is affected by both environmental and genetic factors. Disturbances in differentiation, migration and proliferation of neural crest cells and interactions between the mesenchymal and epithelial cells within the initiation of odontogenesis seem to increase these conditions (5). Multiple supernumerary teeth has been shown to be uncommon in individuals without any associated diseases or syndromes. (13) Some examples of Syndromes associated with hypo-hyperdontia are Down syndrome, Dubowitz syndrome, Ellis-van Creveld syndrome, fucosidosis, G/BBB syndrome, Marfan syndrome, cleft palate with cervical vertebrae abnormalities, and bilateral cleft lip and palate. Furthermore, some anomalies have been proposed to be associated with hypo-hyperdontia such as Taurodontism, dens evaginatus and double tooth. (1) Our case had neither a syndromic condition nor cleft and other dental anomalies. Mesiodens is the most common supernumerary tooth which arises in the maxillary midline. The most frequent complications of mesiodens are the delay or prevention of eruption (26%–52%) and the displacement/rotation (28%–60%) of maxillary permanent incisors. Diastema, Crowding, cyst formation, dilaceration of

permanent teeth, and eruption into the nasal cavity are presumed to be relatively less common complications.(15) Compromising the esthetics and sighting of implants, complicate procedures like alveolar bone grafting, and impinge on nerves causing paresthesia and/or pain have also been reported as complications of mesiodens.(16) In the described case, mesiodens cause median diastema and the rotation of both central incisors in the alveolar process especially the right one adjacent to the impacted mesiodens. Similar to our report, Hundal et al, presented a case with double mesiodens, erupted on the palatal aspect of the anterior maxillary region. One of them was conical and another one was molariform in shape, leading to the labial displacement of the left central incisor. Although, no concomitant missing was reported in their case. (3) Currently, early removal of supernumerary teeth is recommend by most authors, since the delayed removal can cause the altered eruptive potential of the impacted tooth and loss of the arch length, which necessarily need extensive surgical and/or orthodontic interventions. Moreover, complications in the adjacent permanent teeth, such as increased root resorption may result from delayed removal.(17) In the case of the delayed eruption of a central incisor



due to the presence of mesiodens, prior to any surgical or orthodontic interventions, it has been advised to wait at least 6 months for the spontaneous eruption after the extraction of the supernumerary tooth.(18) In this case, both mesiodentes were extracted as soon as possible and after watchful waiting for 6 months both central incisors erupted spontaneously. In order to lessen the risk of damage to the permanent teeth and noble structures, a careful planning before surgery is essential to localize the teeth accurately. For determining the exact location of supernumerary and impacted teeth, intraoral examination and panoramic radiography, alone, are inadequate.(19) CBCT (cone beam

computed tomography) provide comprehensive pictures in 3 planes which can help the surgeon in choosing the proper surgical approach, determining the tooth that should be extracted, and decreasing the amount of surgical trauma on the adjacent hard and soft tissues.(20) In the present case, valuable information for determining the accurate 3D position and morphology of the supernumerary teeth was provided by CBCT.

Since there is no standard treatment protocol for hypo-hyperdontia, its treatment is challenging. (5) Early diagnosis allows the clinician to implement the most appropriate treatment to minimize future complications and is essential for proper management (1).

### References

1. Mallineni SK, Nuvvula S, Cheung AC, Kunduru R. A comprehensive review of the literature and data analysis on hypo-hyperdontia. *J Oral Sci.* 2014;56(4):295-302.
2. Polder BJ, Van't Hof MA, Van der Linden FP, Kuijpers-Jagtman AM. A meta-analysis of the prevalence of dental agenesis of permanent teeth. *Community Dent Oral Epidemiol* 2004;32(3):217-26.
3. Hundal KD, Kaur RD, Sharma SK, Banik S, Singh K. Occurrence of double mesiodens and an inverted mesioden: a report of 2 rare cases. *Oral Surg Oral Med Oral Pathol Oral Radiol.* 2016;2(3):187-9.
4. Russell KA, Folwarczna MA. Mesiodens-diagnosis and management of a common supernumerary tooth. *J Can Dent Assoc.* 2003;69(6):362-7.
5. Anthonappa RP, Lee C-K, Yiu CK, King NM. Hypohyperdontia: literature review and report of seven cases. *Oral Surg Oral Med Oral Pathol Oral Radiol Endod.* 2008;106(5):e24-e30.
6. Brook A, Elcock C, Al-Sharood M, McKeown H, Khalaf K, Smith R. Further studies of a model for the etiology of anomalies of tooth number and size in humans. *Connect Tissue Res.* 2002;43(2-3):289-95.

7. Zadurska M, Sieminska-Piekarczyk B, Maciejak D, Wyszomirska-Zdybel B, Kuroł J. Concomitant hypodontia and hyperodontia—an analysis of nine patients. *Acta odontologica Scandinavica*. 2012;70(2):154-9.
8. Sharma A. A rare case of concomitant hypo-hyperdontia in identical twins. *Indian Soc Pedod Prev Dent*. 2008;26(6):79.
9. Gupta S, Popat H. A clinical report of nonsyndromic concomitant hypo-hyperdontia. *Case reports in dentistry*. 2013;2013.
10. Camilleri G. Concomitant hypodontia and hyperodontia. Case report. *Br Dent J*. 1967;123(7):338.
11. Gibson A. Concomitant hypo-hyperodontia. *Br J Orthod*. 1979;6(2):101-5.
12. Segura JJ, Jiménez-Rubio A. Concomitant hypohyperdontia: simultaneous occurrence of a mesiodens and agenesis of a maxillary lateral incisor. *Oral Surg Oral Med Oral Pathol Oral Radiol Endod*. 1998;86(4):473-5.
13. Varela M, Arrieta P, Ventureira C. Non-syndromic concomitant hypodontia and supernumerary teeth in an orthodontic population. *Eur J Orthod*. 2009;31(6):632-7.
14. Vastardis H. The genetics of human tooth agenesis: new discoveries for understanding dental anomalies. *Am J Orthod Dentofacial Orthop*. 2000;117(6):650-6.
15. Rana SS, Ohri N. Double mesiodens in mixed dentition period: Report of 3 cases. *SRM J Res Dent Sci*. 2018;9(3):125.
16. Krishnamurthy DNH, Unnik DS. twin mesiodens: A case report”. *Int J Curr Res*.
17. Omer RS, Anthonappa RP, King NM. Determination of the optimum time for surgical removal of unerupted anterior supernumerary teeth. *Pediatr Dent*. 2010;32(1):14-20.
18. Amrita Sujlana M, Parampreet Pannu M, Japneet Bhangu B. Double mesiodens: a review and report of 2 cases. *Gen Dent*. 2017.
19. Omami M, Chokri A, Hentati H, Selmi J. Cone-beam computed tomography exploration and surgical management of palatal, inverted, and impacted mesiodens. *Contemp Clin Dent*. 2015;6(Suppl 1):S289.
20. Salgado H, Mesquita P. Impactation of a permanent central maxillary incisor by the presence of two mesiodens: Case report. *Rev Port Estomatol Cir Maxilofac*. 2017;58(1):58-63.