

Premature Eruption and Taurodontism of a Mandibular First Premolar Tooth due to Trauma: A Case Report

Case Report

Abstract

Introduction: Traumatic injuries to deciduous teeth may result in injuries to the succedaneous permanent teeth due to the close proximity between the apex of the deciduous teeth and the permanent tooth bud.

Case presentation: The aim of this case report is to present a case of premature eruption and taurodontism of a mandibular permanent premolar tooth subsequent to the extraction of the mandibular deciduous first molar tooth due to trauma.

Conclusion: Considering the relatively high prevalence rate of trauma in very young children, it is important to gain knowledge about the late complications of traumatic injuries.

Key words: Dental trauma, taurodontism, tooth eruption

Milani Sh¹
Hosseinipour Z²
Hosseini Z^{3*}

1. Assistant Professor, Department of Pediatric Dentistry, Tehran University of Medical Sciences, Tehran, Iran

2. Assistant Professor, Department of Pediatric Dentistry, Faculty of Dentistry, Aja University of Medical Sciences, Tehran, Iran.

3. Assistant Professor, Department of Pediatric Dentistry, Faculty of Dentistry, Kermanshah University of Medical Sciences, Kermanshah, Iran

Corresponding Author:
zahrahosseini69@gmail.com

رویش زودهنگام و تارودنتیسم دندان پرمولر اول مندیبل بعلت تروما: گزارش مورد

چکیده

گزارش مورد

شبیم میلانی^۱زهره سادات حسینی پور^۲زهره حسینی^{۳*}

۱. استادیار بخش دندانپزشکی کودکان، دانشکده دندانپزشکی دانشگاه علوم پزشکی تهران، تهران، ایران.

۲. استادیار بخش دندانپزشکی کودکان، دانشکده دندانپزشکی دانشگاه علوم پزشکی ارتش، تهران، ایران.

۳. استادیار بخش دندانپزشکی کودکان، دانشکده دندانپزشکی دانشگاه علوم پزشکی کرمانشاه، کرمانشاه، ایران.

نویسنده مسئول: دکتر زهره حسینی

zahrahosseini69@gmail.com

تاریخ دریافت: ۹۷/۱۱/۴

تاریخ پذیرش: ۹۸/۹/۲۲

مقدمه: تروما در دندان های شیری به دلیل ارتباط نزدیک بین اپکس دندان شیری و جوانه دندان دائمی، می تواند موجب آسیب به دندان های دائمی جایگزین شونده شود.

گزارش مورد: هدف از مطالعه حاضر، گزارش یک مورد رویش زودهنگام و تارودنتیسم دندان پرمولر مندیبل متعاقب کشیدن دندان مولر اول شیری بعد از تروما است.

نتیجه گیری: با توجه به شیوع نسبتا بالای تروما در سنین پایین کودکی، شناخت عوارض و پیامدهای دیررس آن اهمیت زیادی دارد.

کلمات کلیدی: آسیب های دندانی، تارودنتیسم، رویش دندان

Introduction: Deciduous teeth and the permanent teeth replacing them are considered a single set, with mutual effects on each other. Such a relationship is affected by trauma or dental caries (1). Andresen and Ravn reported frequencies of 28% and 32% for traumatic injuries of deciduous teeth in girls and boys, respectively, and frequencies of 19% and 26% for these injuries in permanent teeth in girls and boys,

respectively (2). In another study by Flores, the prevalence of traumatic injuries in children <6 years of age was reported to be 11-30% (3). The maxillary central incisors are more susceptible to traumatic injuries due to their position in the dental arch and a high rate of exposure (4). Crown-root fractures are seldom seen in deciduous molar teeth and they comprise only 0.8% of all the traumatic injuries to deciduous teeth (5).

Such traumas in permanent teeth might occur in two ways: 1) Direct trauma to the bud of the permanent tooth due to the impact of the apex of the root of the deciduous tooth; 2) Indirectly due to the necrosis of the pulp of the deciduous tooth and periapical infection (3, 6). Early loss of deciduous teeth occurs as avulsion during trauma or tooth extraction due to the late complications subsequent to other types of injuries (7). Premature eruption occurs after some local factors such as trauma, dentoalveolar abscess in deciduous teeth and some systemic conditions and syndromes such as diabetes, hyperthyroidism, congenital adrenal hyperplasia, premature puberty, hemifacial hypertrophy, Sturge-Weber syndrome, osteogenesis imperfecta, Sotos syndrome, Turner's syndrome, pachyonychia congenita and infiltrating lipomatosis (8-10). Taurodontism (bull-like tooth) is a disturbance of the tooth with an overall prevalence rate of 0.25-11.3% (11). This anomaly is seen in both deciduous and permanent dentition; however, it has a lower prevalence in primary dentition (12). The diagnosis of this condition is based on radiographic evaluations (13). In this anomaly the bifurcation/trifurcation area moves apically, resulting in a greater height of the pulp chamber in the occlusogingival

direction (14). Taurodontism might occur as a solitary anomaly (11) or it might be associated with some genetic syndromes (15) such as amelogenesis imperfecta, Down syndrome, Apert syndrome, ectodermal dysplasia, tricho-dento-osseous syndrome, Mohr syndrome, congenital dyskeratosis, hypophosphatasia, Williams syndrome, etc. (16). In addition, it might occur subsequent to radiotherapy and chemotherapy (17), a history of bone marrow transplantation (18) and infection (osteomyelitis) (19). Considering the relatively high prevalence of trauma in young children, it is very important to have knowledge about the late complications of these traumas in order to control and follow the status of patients and inform parents about these conditions. Here, we report a case of premature eruption and taurodontism of a mandibular premolar tooth subsequent to the extraction of a deciduous first molar tooth subsequent to trauma.

Case report : The case presented here was a 5-year-old boy, referring to the Department of Pediatric Dentistry, Faculty of Dentistry, Tehran University of Medical Sciences. Based on the parents' report, the child had sustained a traumatic injury to the chin due to a fall from his bicycle, resulting in the extraction of the mandibular deciduous first molar on the left side as a result of its fracture

after the accident. The child was referred to the Department of Pediatric Dentistry a year after trauma. He was healthy systematically and in the first session his intraoral and extraoral examinations and occlusion were normal. The teeth in his oral cavity at the time of referral consisted of all the upper and lower deciduous teeth except for the left mandibular deciduous first molar tooth. The left mandibular first premolar tooth had erupted in his oral cavity, which exhibited grade II mobility on clinical examination, with an open apex on radiographic examinations along with a widespread radiolucency encompassing the tooth bud (Figures 1 and 2). Oral hygiene instructions were provided to his mother, consisting of using the chlorhexidine mouthwash locally around the affected tooth. After approximately 3 months, due to the defects in

the crown and early caries, the premolar tooth underwent indirect pulp treatment (IPC) and the crown was restored with glass-ionomer, followed by a periapical radiographic examination (Figure 3). The patient was followed every three months for two years. During the follow-up sessions, the patient underwent clinical and periapical radiographic examination of the affected tooth, and the glass-ionomer restoration was modified if indicated. Radiographic examinations during the follow-up sessions showed apical migration of the furcation, resulting in an increase in the occlusogingival height of the pulp chamber. These changes showed the formation of taurodontism in the affected tooth (Figure 4). Finally, an SSC was fabricated for the premolar tooth (Figure 5). The tooth is still functional and is continuing its development.

Figure 1: The intraoral clinical view of the patient in his first visit to the clinic.

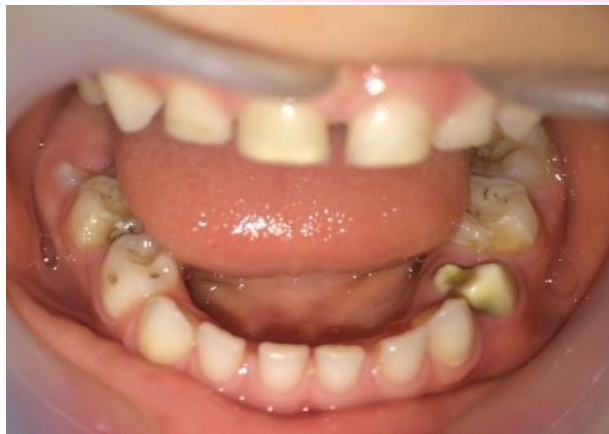

Figure 2: Periapical radiograph of the left mandibular first premolar in the first visit to the clinic.

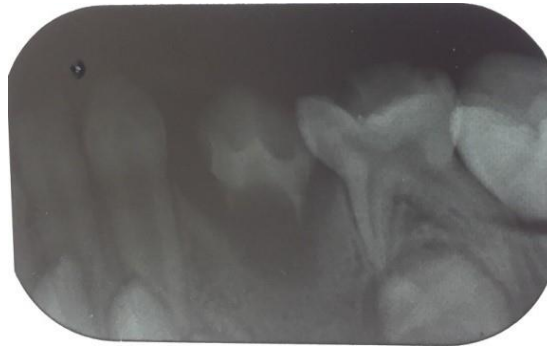


Figure 3: A) The intraoral clinical view of the patient three months after the first visit. B) The intraoral clinical view of the patient after restoration with glass-ionomer.

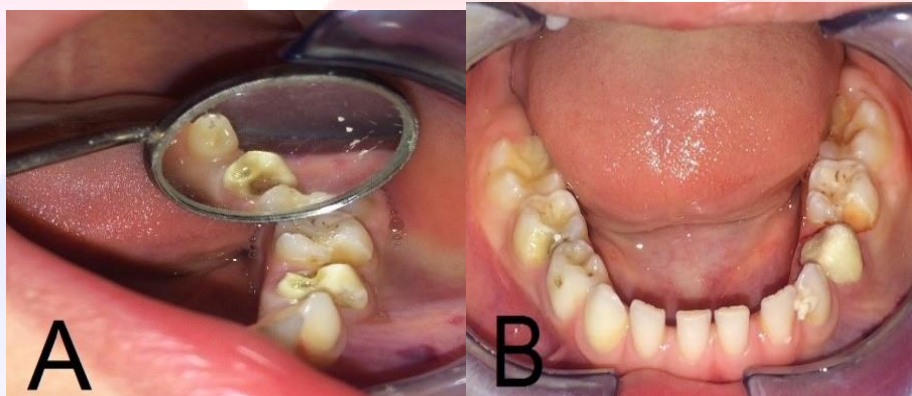


Figure 4: Periapical radiographs of the left mandibular first premolar tooth during the patients' follow-up visits. A) Three months after the first visit. B) One year after the first visit.

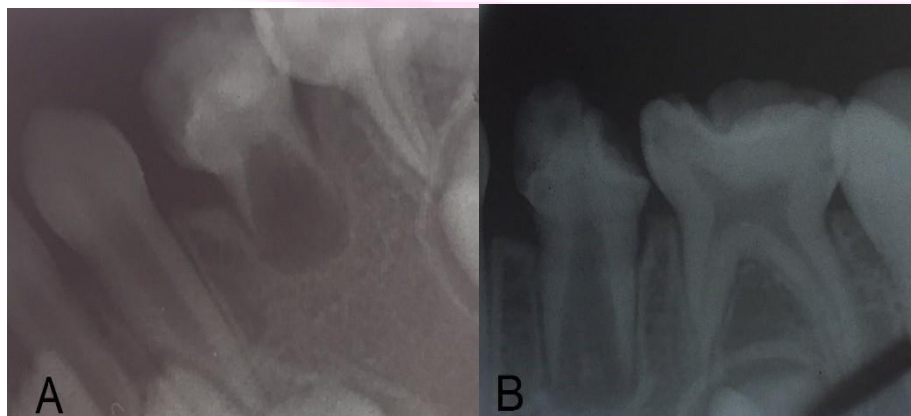
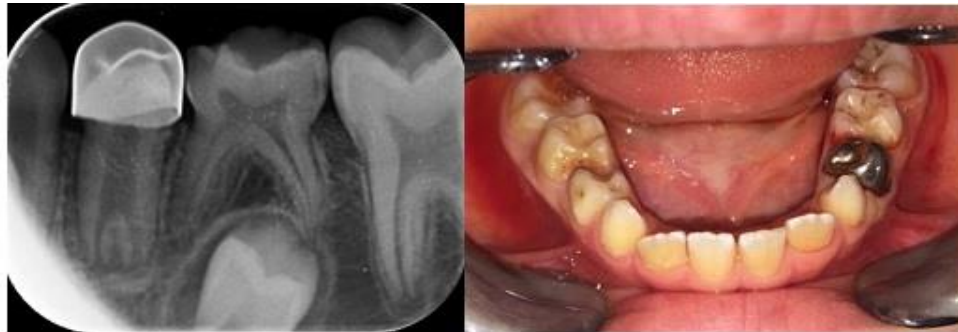
Figure 5: The intraoral clinical and intraoral radiographic views of the patient after placing an stainless steel crown for the left mandibular first premolar.



Discussion: Traumatic injuries comprise the second most important reason for visiting a pediatric dentist, only second to dental caries (20). Traumatic injuries to deciduous teeth might result in structural defects or a change in the position of the developing permanent teeth (21). The most common defects in permanent teeth subsequent to traumatic injuries of deciduous teeth include yellow or white opacities, enamel hypoplasia, root angulation, crown dilaceration, lack of development of the root and eruptive disturbances (22-24). Knowledge about these complications in parents is of utmost importance for prompt referral, follow-up of the patient's status and the required treatment. One of the complications that might occur subsequent to traumas to deciduous teeth is eruptive disturbances in permanent teeth, including premature eruption, delayed eruption (25), impaction (21) and ectopic eruption (21). In the present report, three

months after extraction of the mandibular deciduous first molar, due to trauma, the permanent first premolar tooth had erupted on the same side. Vital pulp therapy (indirect pulp capping) was carried out for the full development of the tooth root. The treatment plan in the present study was consistent with that in the study by Atabek et al (2015). They reported the case of a 6-year-old girl with premature eruption of the mandibular left permanent second premolar tooth after extraction of the carious deciduous second molar tooth at 5 years of age. After the sensitivity of the tooth in question to cold and sweets and its mobility, IPC treatment was carried out, followed by splinting of the tooth #35 to tooth #36. In that study, full development of the tooth and apex was observed (26). In the present case, the patient was followed for two years until the root developed completely and the apex closed. An important consideration during the

follow-up period in the present study was that the furcal area moved apically over time and the occlusogingival height of the pulp chamber increased, indicating that the tooth underwent taurodontism. No signs of taurodontism were found in the subject's other teeth; it should be pointed out that in half of the cases taurodontism occurs bilaterally (27). Considering the widespread radiolucency detected on the radiograph and very premature eruption of the premolar tooth, it might be postulated that the mandibular deciduous first molar tooth might have been infected due to the fracture resulting from trauma at the time of extraction or it had been extracted because of severe infection irrelevant to the traumatic accident. Infection of a deciduous tooth is one of the factors that leads to the ectopic eruption or premature eruption of the succedaneous permanent tooth (28, 29). On the other hand, Reichart and Quast (1975) reported that taurodontism might occur after direct infection of the developing root (19). Therefore, it is possible that the etiology of taurodontism and premature eruption of the mandibular premolar tooth in the present case was infection of the deciduous molar tooth and its transmission to the succedaneous permanent tooth bud due to the trauma. This is important for the follow-up of the patient

and for rendering the necessary treatment. Apart from the complexity of endodontic treatment of these teeth, the periodontal status of such teeth should also be taken into account because subsequent to periodontal pocket formation or gingival recession, they are affected by furcal involvement at a lower rate compared to normal teeth and teeth with taurodontism exhibit significant periodontal destruction before furcal involvement (30). Therefore, if such anomaly is seen in any tooth, the patients and parents should be provided with the necessary instructions on the care and prevention of periodontal diseases.

Conclusion: Considering the relatively high prevalence rate of trauma in very young children, it is important to gain knowledge about the late complications of traumatic injuries. It is advisable to provide instructions for parents for the care and follow-up of the dental status of children in future at the time of traumatic injuries. In addition, this can help the dentist render the necessary treatment at the correct time to the patient. On the other hand, based on the current case report, a permanent tooth might undergo taurodontism after traumatic injury of a deciduous tooth. However, further studies are necessary in this area.

References

1. Mallineni SK, Nuvvula S, Cheung AC, Kunduru R. A comprehensive review of the literature and data analysis on hypo-hyperdontia. *J Oral Sci.* 2014;56(4):295-302.
2. Polder BJ, Van't Hof MA, Van der Linden FP, Kuijpers-Jagtman AM. A meta-analysis of the prevalence of dental agenesis of permanent teeth. *Community Dent Oral Epidemiol* 2004;32(3):217-26.
3. Hundal KD, Kaur RD, Sharma SK, Banik S, Singh K. Occurrence of double mesiodens and an inverted mesiodens: a report of 2 rare cases. *Oral Surg Oral Med Oral Pathol Oral Radiol.* 2016;2(3):187-9.
4. Russell KA, Folwarczna MA. Mesiodens—diagnosis and management of a common supernumerary tooth. *J Can Dent Assoc.* 2003;69(6):362-7.
5. Anthonappa RP, Lee C-K, Yiu CK, King NM. Hypohyperdontia: literature review and report of seven cases. *Oral Surg Oral Med Oral Pathol Oral Radiol Endod.* 2008;106(5):e24-e30.
6. Brook A, Elcock C, Al-Sharood M, McKeown H, Khalaf K, Smith R. Further studies of a model for the etiology of anomalies of tooth number and size in humans. *Connect Tissue Res.* 2002;43(2-3):289-95.
7. Zadurska M, Sieminska-Piekarczyk B, Maciejak D, Wyszomirska-Zdybel B, Kurol J. Concomitant hypodontia and hyperodontia—an analysis of nine patients. *Acta odontologica Scandinavica.* 2012;70(2):154-9.
8. Sharma A. A rare case of concomitant hypo-hyperdontia in identical twins. *Indian Soc Pedod Prev Dent.* 2008;26(6):79.
9. Gupta S, Popat H. A clinical report of nonsyndromic concomitant hypo-hyperdontia. *Case reports in dentistry.* 2013;2013.
10. Camilleri G. Concomitant hypodontia and hyperodontia. Case report. *Br Dent J.* 1967;123(7):338.
11. Gibson A. Concomitant hypo-hyperodontia. *Br J Orthod.* 1979;6(2):101-5.
12. Segura JJ, Jiménez-Rubio A. Concomitant hypohyperdontia: simultaneous occurrence of a mesiodens and agenesis of a maxillary lateral incisor. *Oral Surg Oral Med Oral Pathol Oral Radiol Endod.* 1998;86(4):473-5.
13. Varela M, Arrieta P, Ventureira C. Non-syndromic concomitant hypodontia and supernumerary teeth in an orthodontic population. *Eur J Orthod.* 2009;31(6):632-7.
14. Vastardis H. The genetics of human tooth agenesis: new discoveries for understanding dental anomalies. *Am J Orthod Dentofacial Orthop.* 2000;117(6):650-6.
15. Rana SS, Ohri N. Double mesiodens in mixed dentition period: Report of 3 cases. *SRM J Res Dent Sci.* 2018;9(3):125.
16. Krishnamurthy DNH, Unnik DS. twin mesiodens: A case report”. *Int J Curr Res.*
17. Omer RS, Anthonappa RP, King NM. Determination of the optimum time for surgical removal of unerupted anterior supernumerary teeth. *Pediatr Dent.* 2010;32(1):14-20.
18. Amrita Sujlana M, Parampreet Pannu M, Japneet Bhangu B. Double mesiodens: a review and report of 2 cases. *Gen Dent.* 2017.
19. Omami M, Chokri A, Hentati H, Selmi J. Cone-beam computed tomography exploration and surgical management of palatal, inverted, and impacted mesiodens. *Contemp Clin Dent.* 2015;6(Suppl 1):S289.
20. Salgado H, Mesquita P. Impactation of a permanent central maxillary incisor by the presence of two mesiodens: Case report. *Rev Port Estomatol Cir Maxilofac.* 2017;58(1):58-63.