

Dentinogenesis Imperfecta type II: A case report

Moini P*, Afsharian Zadeh M**, Abdoli Tafti E**

* Assistant professor, pediatric department, Islamic Azad University, Tehran, Iran

** Postgraduate student, pediatric department, Islamic Azad University, Tehran, Iran

Abstract

Dentinogenesis Imperfecta type II or hereditary opalescent dentin is inherited as an autosomal dominant trait, that affects both primary and permanent dentition. It occurs in both sex. Clinically, this disorder is characterized by yellowish brown teeth with structural defects such as bulbous crown and small pulp chambers, radiographically. The underlying defect of mineralization often results in shearing of the overlying enamel; leaving exposed weakened dentin which is prone to wear. In this article, a 6 year old Iranian boy with Dentinogenesis Imperfecta and his recommended treatment plan is reported.

Introduction:

Dentinogenesis Imperfecta(DI) is a type of autosomal dominant inherited anomaly of dentin (1) that has an incidence of 1 in 6000 to 1 in 8000 (2). The primary anomalies of DI are in structure and formation of dentin (1) that results from mutations in genes encoding the major protein of it (2). Shield's et al classified DI based on phenotypic variability (3):

(I): that occurs with osteogenesis imperfecta

(II): hereditary opalescent dentin

(III): Brandywine type

In DI type I, the dentin mineralization defects are coupled with osteogenic imperfect, characterized by systemic conditions such as bone fragility, blue sclera, joint laxity and hearing impairment. DI-II has the same dentin defects as DI_I, but is not related to any collagen defects or osteogenic component. DI-III is a complex heterogenous disorder, occurring in an isolated racial group.(4)

DI type II was probably first recognized by Barret in 1882(5). The term dentinogenesis imperfecta was coined by Robert and Schour in 1993(5). This anomaly

is also named as Capdepon't's teeth, hereditary opalescent dentin, hereditary brown teeth etc (6). Clinically it is characterized by opalescent and translucent dentin (6). In DI type II both primary and permanent dentitions are equally affected. Periapical radiolucencies, bulbous crown, obliteration of pulp chambers and root fractures are evident. (3)

Radiographically, DI teeth have short roots constricted in their cervical regions and obliterated pulp chambers (1).

Histologically, the thickness and structure of the enamel is normal. The dentinoenamel junction appears smooth and uniform because it lacks the usual scalloped topography. The mantle dentin is usually normal, but in other areas, it presents scarce dentinal tubules that are small, irregular, and usually obliterated with no evident lumen and atubular dentin can be observed.(7)

Treatment of DI type II requires a multidisciplinary approach, esthetic is an important factor. Restorative treatment focuses on retaining the remaining teeth structure and protecting the affected dentin from caries

and attrition. (1) Early diagnosis and treatment is mandatory in these cases, because delay in treatment can cause partial or complete loss of clinical crowns with healthy roots. (8)

Case:

A 6 year old boy was referred to the department of Pediatric dentistry, Dental College, Islamic Azad University, Tehran, Iran complaining of ugly appearance of his teeth. He had no pain and no abscess formation. A review of system revealed nothing specific. There was a similar problem in his father, 2aunts, and paternal grandmother and some other paternal family members according to his mother. Extra-oral examination revealed no swelling, no facial asymmetry and lymph nodes were not palpable. Intra-oral examination revealed that occlusion was half cusp class II on both sides, oral hygiene was fair. Oral

mucosa was normal, no abscess formation was evident. All primary teeth (except mandibular primary incisor), the permanent first molars and mandibular incisors were present. Both deciduous and permanent teeth were affected, but involvement of permanent teeth was less than deciduous. All teeth were yellowish to blue in color and it seemed that they had normal size. They had moderately attrition. Maxillary and mandibular primary molars and canines and maxillary left central incisor had caries. (Fig 1)

Periapical and panoramic radiographs showed features characteristics of DI. Bulbous crowns of the teeth and short and slender roots were evident. Pulp chambers were absent. It seemed that periapical radiolucencies were present around the apex of maxillary primary first molars and maxillary primary second molars. (fig 2 and 3)

Fig1: Clinical examination

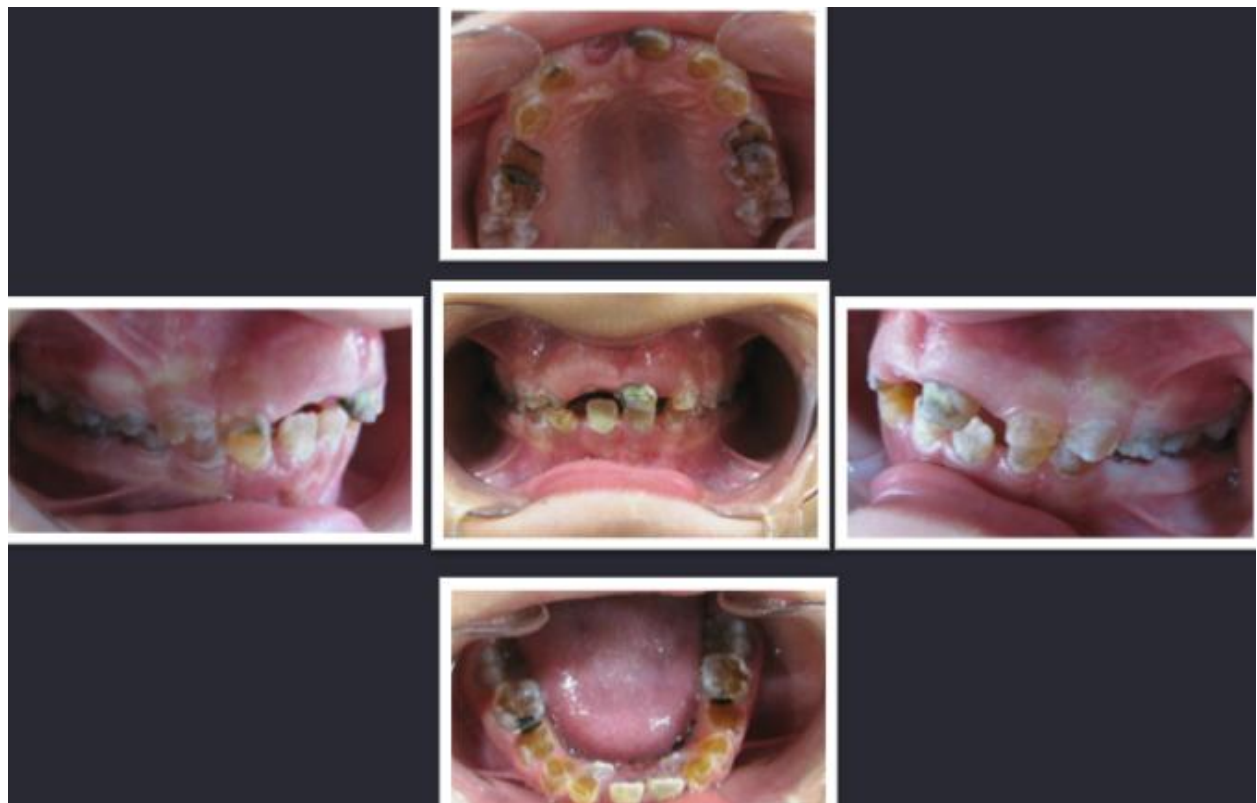

Fig 2: Intra oral radiographic examination


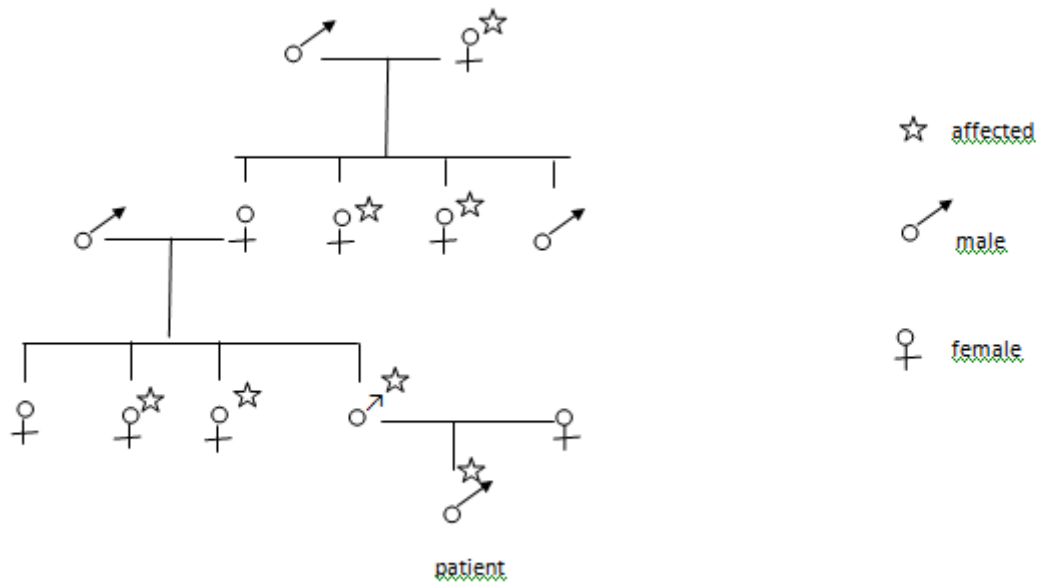


Fig 3: Panoramic view of the patient

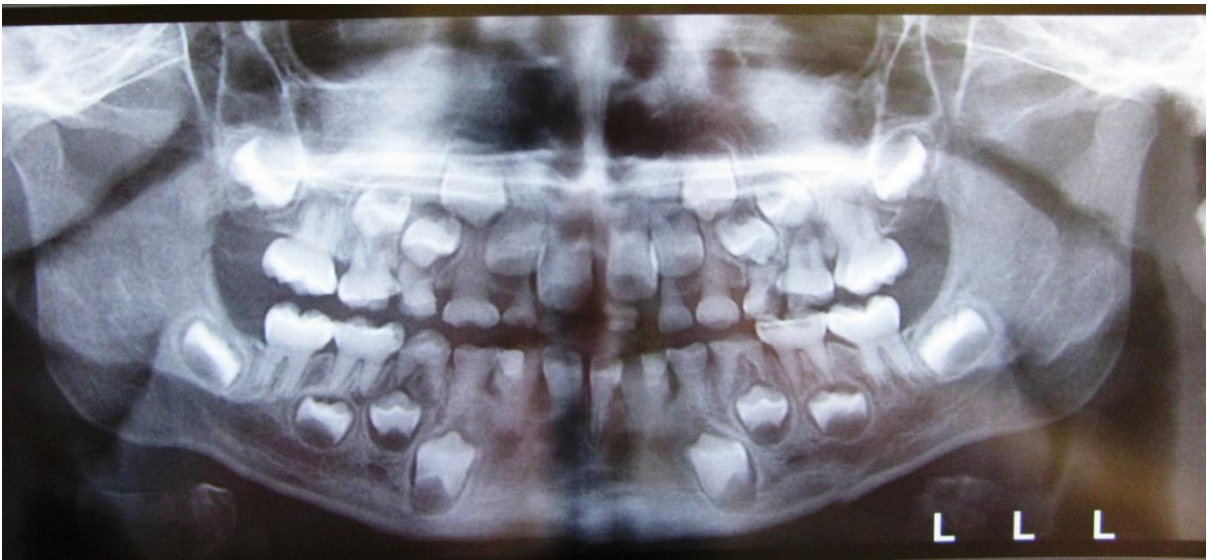

Fig 4- Genetic tree of patient's family



On the basis of clinical and radiographic findings, a diagnosis of dentinogenesis imperfecta was made. Patient was advised for extraction of mandibular first molars, maxillary primary molars and restoring the mandibular second molars with stainless steel crown. It was recommended to restore primary canines with veneered stainless steel crown. Also, fissure sealant therapy for the permanent first molars seemed necessary.

Overlay denture seemed ideal for rehabilitating the oral function and occlusion, but in our case, a mandibular lingual holding arch and maxillary nance appliance is recommended.

Discussion:

Opalescent dentin was first described by Barret in 1882. This condition occurs in 1 in every 8000 birth, and is result of a mutation in the DSPP gene (Dentin Sialoprotein Protein) (9). The family pedigree chart (figure 4) for the father and son shows six affected members over four generation. The child's father, two paternal aunts, and two aunts of his father are affected.

The aim of treatment of children with DI is to ensure favorable condition for eruption of permanent teeth, caries prevention, attrition, observation and monitoring of skeletal development. If the deciduous teeth begin to wear, placement of artificial crowns is recommended before excessive loss of tooth structure occurs.

During treatment planning, several factors such as age of the patient, extent of dental caries, periapical involvement, pulp canal anatomy and abnormalities and prosthodontic needs of the patient should be considered.

In this case, almost all primary molars were decayed, and except two mandibular molars had to be extracted due to periapical abscess. Although the extent of caries was moderate, nearly all primary molars had periapical lesions. Also, it was a need to have a caries free environment to ensure a healthy permanent dentition.

As the patient seemed non-cooperative for wearing the partial dentures, we decided to put a mandibular lingual holding arch and a maxillary nance appliance for space maintaining.

It is said that those with DI in the primary dentition may be absent of DI in the permanent dentition (6). Therefore, we considered fissure sealant therapy for the permanent first molars and a timed follow up visits (every 3 months) for the patient.

As hereditary opalescent dentin is an autosomal dominant disease, once the child diagnosed with Dentinogenesis imperfecta, other family members should be examined thoroughly.

References:

1. Shetty N, Joseph M, Basnet P, Dixit S. An integrated treatment approach: a case report for dentinogenesis imperfecta type II. Kathmandu Univ Med J. 2007; 5(2):230-3.
2. Barron MJ, McDonnell ST, Mackie I, Dixon MJ. Hereditary dentin disorders: dentinogenesis imperfecta and dentin dysplasia. Orphanet J Rare Dis. 2008; 3:31.
3. Pinkham J, Casamassimo P, MCTigue D, Fields H. Pediatric dentistry: Infancy through adolescence. 4th Ed. Philadelphia: Elsevier Saunders; 2005.
4. Mott D, Patel M, Park DC. Dental rehabilitation of a patient with dentinogenesis imperfecta: a clinical report. The army medical department journal. 2011:95-7.
5. Kamboj M, Chandra A. Dentinogenesis imperfecta type II: an affected family saga. J Oral Sci. 2007; 49(3):241-4.
6. Tsai CL, Lin YT, Lin YT. Dentinogenesis imperfecta associated with Osteogenesis imperfecta: report of two cases. Chang Gung Med J. 2003; 26:138-43.
7. Delgado AC, Ruiz M, Alarcon JA, Gonzalez E. Dentinogenesis imperfecta: the importance of early treatment. Quintessence Int. 2008; 39(3):257-63.
8. Goud A, Deshpande S. Prosthodontic rehabilitation of dentinogenesis imperfecta. Contemp Clin Dent. 2011; 2(2):138-41.
9. Gupta S, Bhowate R, Bhati A. Hereditary opalescent dentin: a report of two cases. J Contemp Dent Pract. 2010; 11(4):1-5.